

# Effect of Pyocyanin Extracted from *Pseudomonas Aeruginosa* on the Testicular Tissue in a Mouse Model

Zainab K. Abd aljalil<sup>1\*</sup>, Kawakib I. Al-zubaidy<sup>2</sup>, Alaa S. Kadhim<sup>3</sup>

<sup>1</sup>Zainab K. Abd aljalil, MSc student Department of Biology- Qurna Education Collage\ University of Basrah, <https://orcid.org/0009-0002-7383-6610>

<sup>2</sup>Asst. Prof. Kawakib I. Al-zubaidy, Assist. Prof. Department of Biology- Qurna Education Collage\ University of Basrah <https://orcid.org/0000-0003-0585-1165>

<sup>3</sup>Asst. Prof. Alaa S. Kadhim, Department of Biology- Qurna Education Collage\ University of Basrah, <https://orcid.org/0000-0002-9777-9270>

\*Correspondence to: Zainab Kadhim Abd al jalil  
Email: zainabkadhim316@gmail.com

**Abstract:** The current study aimed to find out the histopathological effects of pyocyanin pigment extracted from the *Pseudomonas aeruginosa* on testicular tissue by studying the histopathological changes in the testes of laboratory mice injected with a concentration of 500 µg/ml of pyocyanin for 30 days.

The results of the histological microscopic examination showed the presence of a number of pathological changes, which were represented after four days of injection by the occurrence of simple cytoplasmic fragmentation of spermatogonia, accumulation of fluid between the seminiferous tubules, and congestion of testicular tissue with the presence of cellular necrosis, loss of some nuclei, their karyopyknotic and degeneration in other cases, and a decrease in the number of mature spermatozoa in the tubular lumen and loss of cellular development of spermatogonia, as well as the cessation of the mitotic activity of spermatogonia and the accumulation of lipid droplets within the tissue. Cases of programmed cell death and detachment of the germinal layer were also observed, in addition to the complete loss of the normal shape of the stages of development of spermatogonia, as well as necrosis of the spermatogenic layers.

**Keywords:** Pyocyanin, *Pseudomonas aeruginosa*, Testis, Histopathology, Spermatogenesis, Mice.

---

## 1. Introduction

*Pseudomonas aeruginosa* (*P. aeruginosa*) is a Gram-negative, motile by one or more flagella, rod-shaped with a length of about (1-5) µm and width of (0.5-1) µm and opportunistic (Diggle and Whiteley, 2020). Pyocyanin is a blue-green phenazine pigment produced by about 90 to 95% of *P. aeruginosa* strains. It is active in oxidation-reduction processes and is considered a secondary metabolite secreted by *P. aeruginosa* (Shouman et al., 2023). Pyocyanin is an aromatic compound containing nitrogen and belongs to the tricyclic phenazines (O'Malley et al., 2004; Fothergill et al., 2007), is one of the most important pigments produced by this bacterium due to its important role in pathogenesis, especially in chronic lung diseases. It protects *Pseudomonas* from the action of cilia of epithelial cells in the respiratory tract and also protects the bacterium from urothelial cells and liver endothelial cells (LSEC) (Hall et al., 2016). Pyocyanin is also toxic to neutrophils (Patel et al., 2016).

This toxicity is due to the ability of pyocyanin to penetrate the cell membrane due to its low molecular weight and to generate reactive oxygen species. This leads to the reduction of the cell cycle, causes significant damage to human cells, affects DNA, and ultimately leads to cell death. In addition to its toxicity, pyocyanin also has antimicrobial, antifungal, and antiprotozoal activities. It also acts as an antioxidant and anticancer agent (Marrez and Mohamad, 2020).

## 2. Material and Methods

### 2.1 Extraction of Pyocyanin Pigment

The pigment was extracted by chloroform followed by extraction steps by acid / base, in order to improve the final yield of pure pyocyanin, as the process of extracting the pyocyanin pigment was based on the oxidative and

reducing properties of the pigment and on the fact that only pure pyocyanin changes color when the pH changes, which made the pigment have a different solubility based on the type of solvent and thus appear red in aqueous solvents and blue in organic solvents and this feature made the purification process of the pyocyanin pigment possible and very effective. By changing the pH and extracting water/chloroform (El Feghali and Nawas, 2018).

## **2.2 Experimental Animals**

The current study used male albino laboratory mice *M. musculus* L belonging to the BALB/C strain, weighing 20-25 g and aged between 10 and 12 weeks. They were bred in the animal house of the Department of Life Sciences, College of Education - Al-Qurna / University of Basrah under controlled conditions of good ventilation, a fixed lighting system of 12 hours light/12 hours dark, and a temperature of 20-25°C. The mice were placed in standard-sized plastic cages (45×30×10 cm) with a floor covered with sawdust that was replaced every two days.

### **2.2.1 Experimental Design**

The laboratory mice were randomly divided into two groups and each group included 15 mice as follows:

**Control Group:** Injected with normal saline at a dose of 0.1 ml for 30 days.

**Pyocyanin-Treated Mice Group:** The laboratory mice were injected intraperitoneally (I.P.) with 0.1 ml of pyocyanin pigment at a concentration of 500 µg/ml for 30 days.

The mice were dissected after anesthesia with chloroform at intervals of (4, 7, 14, 21, 30) days, with 3 replicates in each period of the experiment.

### **2.2.2 Injection Method**

The laboratory mice were injected intraperitoneally (I.P.) with 0.1 ml of normal saline and 0.1 ml of pyocyanin pigment at a concentration of 500 µg/ml.

### **2.2.3 Study of Histopathological Changes**

The method of (Humason, 1972) was used to prepare histological sections of the testes of laboratory mice.

## **3. Results**

The results of the histological examination of testicular tissue injected with pyocyanin pigment at a concentration of 500 µg/ml showed several histological changes compared to the control group. After four days of injection, mild cytoplasmic vacuolization of spermatogonia and fluid accumulation between the seminiferous tubules were observed, as shown in Figures (2 and 3). After seven days of injection, the results showed cellular necrosis, loss of some nuclei, a decrease in the number of mature spermatozoa in the tubular lumen, loss of cellular development of spermatogonia, cessation of mitotic activity of spermatogonia, accumulation of lipid droplets within the tissue, and cases of apoptosis, as shown in Figures (4 and 5).

After fourteen days of injection, the results showed degeneration of Leydig cells, separation of the germinal layer, and karyopyknosis of some nuclei, as shown in Figure (6). After twenty-one days of injection, the microscopic examination showed necrosis and karyolysis in spermatogonia with loss of mature spermatozoa within the tubular lumen, complete loss of the normal shape of the stages of spermatogenesis, and necrosis of the germinal layers, as shown in Figures (7 and 8). After 30 days of the experiment, necrosis of the blood vessel, Leydig cells, and congestion were observed, as shown in Figure (9).

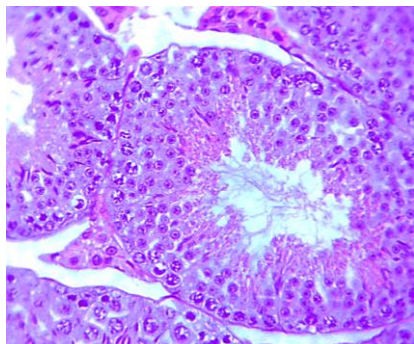


Figure (1): Cross section of testicular tissue in the control group. (400X) (H&E)

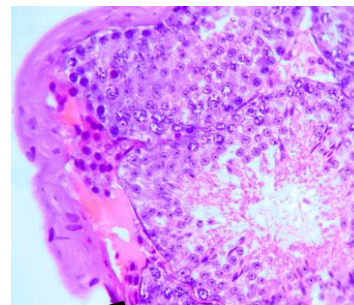


Figure (2): Cross section of testicular tissue 4 days after injection showing accumulation of fluid between the seminiferous tubules. (400X) (H&E)

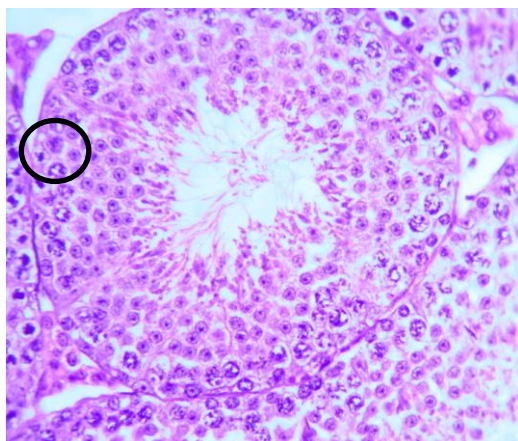


Figure (3): Cross section of testicular tissue 4 days after injection showing mild cytoplasmic vacuolization of the spermatogonia. (400X) (H&E)

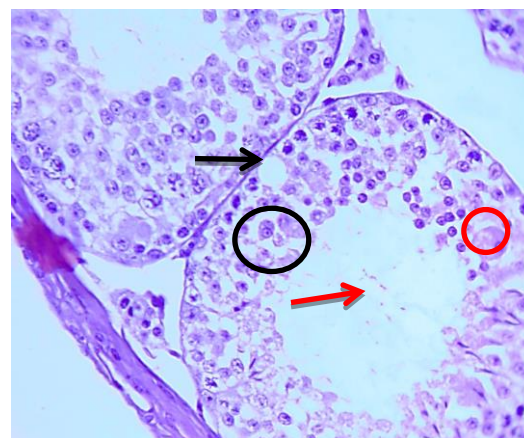


Figure (4): Cross section of testicular tissue 7 days after injection showing accumulation of lipid droplets (black arrow), cessation of mitotic activity of spermatogonia (black circle), apoptosis (red circle), and a decrease and loss of mature spermatozoa (red arrow). (400X) (H&E)

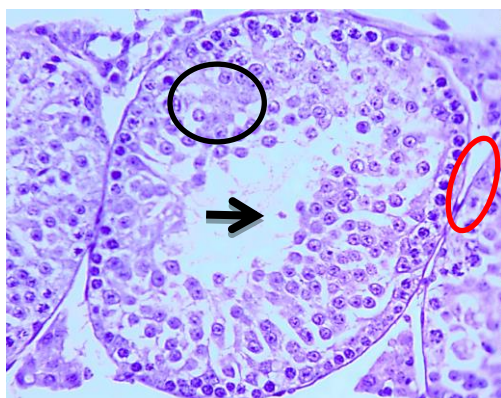


Figure (5): Cross section of testicular tissue 7 days after injection showing cytoplasmic degeneration in spermatogonia (red circle), cellular necrosis and loss of some nuclei (black circle), and a decrease in the number of mature spermatozoa in the tubular lumen (black arrow). (400X) (H&E).

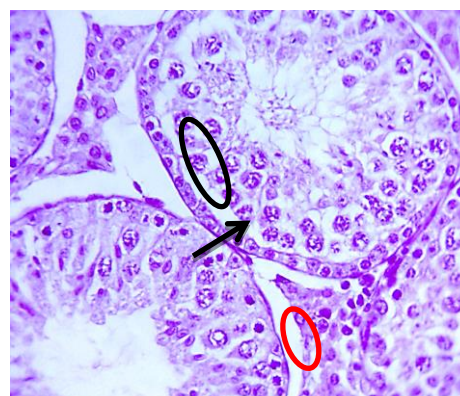


Figure (6): Cross section of testicular tissue 14 days after injection showing degeneration of some spermatogonia (black circle), separation of the germinal layer (arrow), and karyopyknosis (red circle). (400X) (H&E)



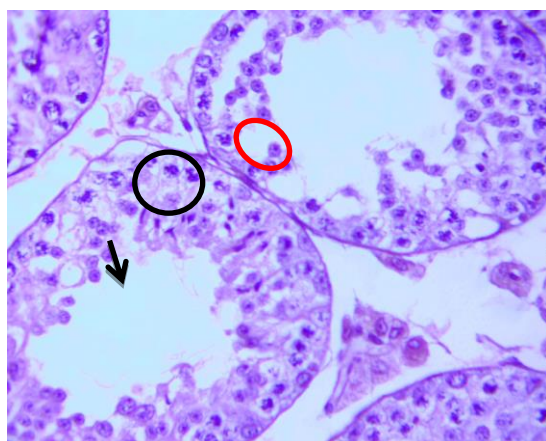


Figure (7): Cross section of testicular tissue 21 days after injection showing necrosis and karyolysis of spermatogonia (black circle), necrosis of the spermatogenic layers (red circle), and loss of mature spermatozoa (arrow). (400X) (H&E).

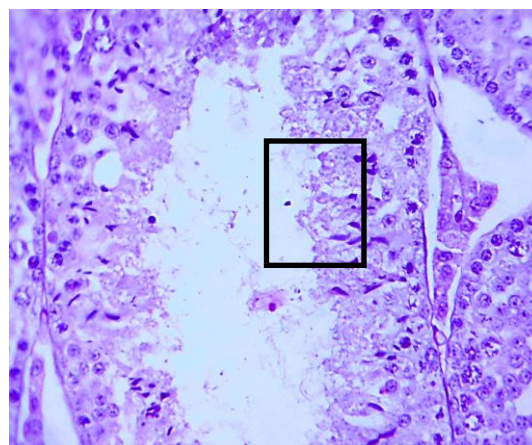


Figure (8): Cross section showing complete loss of the normal morphology of the spermatogenic cell stages 21 days after injection. (400X) (H&E).

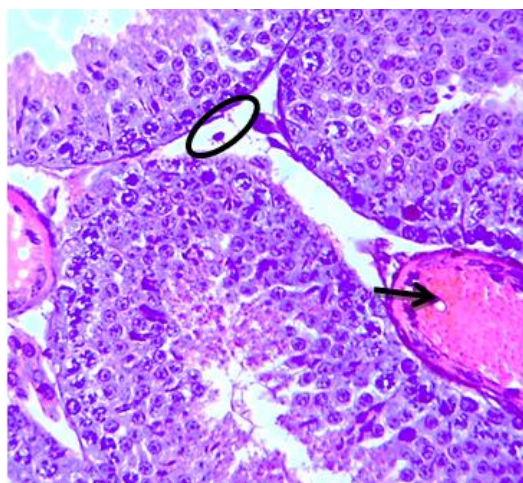


Figure (9): Cross section of testicular tissue 30 days after injection showing necrosis of Leydig cells (circle) and vascular congestion (arrow). (400X) (H&E).

#### 4. Discussions

##### Effect of Anthocyanin Dye on Testicular Tissue

Anthocyanin dye has a low molecular weight that allows it to easily permeate cell membranes. Upon entering these membranes, it is reduced by NADPH, which is followed by the reduction of molecular oxygen to superoxide, which in turn is converted to hydrogen peroxide (Zhao *et al.*, 2014). Consequently, it causes various pathological tissue changes inside the cells. Simple cytoplasmic vacuolation of spermatogenic cells was observed. This condition is considered an adaptation to the pathological state caused by the injected substance affecting the tissue (Abdel Hammed, 2004). These vacuoles accumulate harmful substances and prevent them from interfering with the vital activities of those cells (Cheville, 2009).

The results of the current study showed cytoplasmic degeneration in several areas of the testicular tissue. The reason for this may be the increase in the formation of lipoproteins, which are converted into triglycerides and filtered in the liver. This leads to the appearance of clear vacuoles that push the nucleus to the periphery of the cell (Al-Hamdaui and Al-Hubaity, 2014). Abdel Hammed (2004) stated in his study that nuclear damage follows cytoplasmic damage and indicated that pathological tissue effects transition from reversible to irreversible pathological changes. Cytoplasmic degeneration appeared early before the appearance of changes in the nuclei of testicular cells that were affected by necrosis. This is consistent with the results of the current

study, which observed karyopyknosis and karyolysis of spermatogenic cells leading to necrosis. Karyopyknosis is one of the most prominent morphological features of apoptosis (Karpman et al., 1998).

The karyopyknosis and karyolysis of spermatogenic cells are attributed to the effect of free radicals and reactive oxygen species. They interact with DNA components and negatively affect purine and pyrimidine bases and the DNA backbone, which may lead to significant changes in the cell nuclei and their gradual lysis, in addition to a change in their shape, followed by the final stages of nuclear lysis and cell death (Zhu et al., 2012).

Anthocyanin can potentially cause a reaction in eukaryotes at the level of the cell wall and the mitochondrial respiratory chain. This reaction results in the release of reactive oxygen species from the mitochondria, which accelerates the aging process and apoptosis (Bonifácio et al., 2020; Manago et al., 2015). Pyocyanin pigment undergoes a redox cycle in the presence of various reducing agents and molecular oxygen, which leads to the accumulation of supertoxic oxide and hydrogen peroxide and thus leads to injury or death of cells (Hassan and Fridovich, 1980).

Congestion of the testicular tissue vasculature was also observed. The reason for this may be due to the triggering of inflammatory reactions by chemical mediators such as histamine and prostaglandins, which are secreted by mast cells and other inflammatory cells. These mediators cause vasodilation and a localized increase in blood flow, in addition to increased blood viscosity, which results from the permeability of blood proteins from the endothelial lining of the capillaries, which causes a slow flow of blood in them, and therefore they appear congested with blood (Kumar et al., 2003). Vasodilation allows the passage of large quantities of inflammatory cells from the affected area. They adhere to each other and move in a circular motion, pushing the inflammatory cells from the center to the periphery. They then adhere to the endothelial cells of the blood vessel, thus finding their way out of the vessel due to the increased spaces between the endothelial cells caused by the effect of the external agent (Mitchell et al., 2007).

## 5. Conclusions

Based on the results of the current study, it was found that the pyocyanin pigment can cause a number of histopathological changes in the testicular tissue, and these changes were represented by the occurrence of cytoplasmic abruption and fluid accumulation between the nuclear tubule with a decrease in the number of mature spermatozoa, the loss of some nuclei, the occurrence of cellular necrosis with the accumulation of fatty droplets and other histological changes.

## 6. Reference

1. Abdel Hameed, T. F. (2004). Light and electron microscopic studies on the effect of orally-administered formalin on liver and kidney of guinea pig. *JOURNAL-EGYPTIAN GERMAN SOCIETY OF ZOOLOGY*, 45(C), 203-224.
2. Abdul-Hussein, Z. R., and Atia, S. S. (2016). Antimicrobial effect of pyocyanin extracted from *Pseudomonas aeruginosa*. *European Journal of Experimental Biology*, 6(3), 1-4.
3. Al-Hamdaui, M.Z. and Al-Hubaity, A.Y. (2014). The histological and histochemical changes of the rat's liver induced by 5-fluorouracil. *Iraqi Vet.Sci.* 28(2):95-103.
4. Patel, T. S., Cottreau, J. M., Hirsch, E. B., & Tam, V. H. (2016). Impact of hyperglycemia on outcomes of patients with *Pseudomonas aeruginosa* bacteremia. *Diagnostic Microbiology and Infectious Disease*, 84(2), 155-158.
5. Bonifácio, T. T. C., Arruda, R. R. A., Oliveira, B. T. M., Silva, J. E. G., & Vasconcelos, U. (2020). Exposure to pyocyanin promotes cellular changes in *Candida* spp. *Res. J. Pharm. Biol. Chem. Sci*, 11, 111-119.
6. Kumar V, Cotran R, Robbins L. (2003). Basic Pathology. (7 th ed.) USA: Churchill Livingstone, 102 p
7. Mitchell, R. S., Kumar, V., Abbas, A. K., & Fausto, N. (2007). Robbins basic pathology. *Philadelphia, PA: Saunders*, 8, 72-79.
8. Cheville, N.F. (2009). Ultrastructural pathology: The comparative cellular basis of disease. (2 nd ed.). Wiley-Blackwell. A John Wiley & Sons, Inc. USA. 1000p. Churchill Livingston.
9. Fothergill, J. L., Panagea, S., Hart, C. A., Walshaw, M. J., Pitt, T. L., & Winstanley, C. (2007). Widespread pyocyanin over-production among isolates of a cystic fibrosis epidemic strain. *BMC microbiology*, 7, 1-10.
10. Shouman, H., Said, H. S., Kenawy, H. I., & Hassan, R. (2023). Molecular and biological characterization of pyocyanin from clinical and environmental *Pseudomonas aeruginosa*. *Microbial Cell Factories*, 22(1), 166.

11. Hassan HM, Fridovich I (1980) Mechanism of the antibiotic action of pyocyanine. *J Bacteriol* 141:156–163.
12. Humason, G.L. (1972). *Animal tissue techniques*. Freeman, W.H. (3th ed.). San Francisco press. UAS.PP.641.
13. Karpman, D.; Hakansson, A.; Perez, M.; Isaksson, C.; Corlemalm, E.; Coprioli, A. and Svanbrog, C. (1998). Apoptosis of renal cortical cells in the hemolytic uremic syndrome: invivo and invitro studies . *Infect. Immun.* 66:636-644.
14. Manago, A., Becker, K. A., Carpinteiro, A., Wilker, B., Soddemann, M., Seitz, A. P., ... & Gulbins, E. (2015). *Pseudomonas aeruginosa* pyocyanin induces neutrophil death via mitochondrial reactive oxygen species and mitochondrial acid sphingomyelinase. *Antioxidants & redox signaling*, 22(13), 1097-1110.
15. Marrez, D. A., and Mohamad, H. S. (2020). Biological activity and applications of pyocyanin produced by *Pseudomonas aeruginosa*.
16. Diggle, S.P. and Whiteley, M.(2020).Microbe Profile: *Pseudomonas aeruginosa*: opportunistic pathogen and lab rat. *Microbiology* (Reading). 166(1): 30–33.
17. O'Malley, Y.Q.; Reszka, K.J.; Britigan, B.E. Direct oxidation of 21,71-dichlorodihydrofluorescein by pyocyanin and other redox-active compounds independent of reactive oxygen species production. *Free Radic. Biol. Med.* 2004, 36, 90–100.
18. Parsons, J. F., Greenhagen, B. T., Shi, K., Calabrese, K., Robinson, H., & Ladner, J. E. (2007). Structural and functional analysis of the pyocyanin biosynthetic protein PhzM from *Pseudomonas aeruginosa*. *Biochemistry*, 46(7), 1821-1828.
19. Shouman, H., Said, H. S., Kenawy, H. I., & Hassan, R. (2023). Molecular and biological characterization of pyocyanin from clinical and environmental *Pseudomonas aeruginosa*. *Microbial Cell Factories*, 22(1), 166.
20. Zhao, J., Wu, Y., Alfred, A. T., Wei, P., & Yang, S. (2014). Anticancer effects of pyocyanin on HepG2 human hepatoma cells. *Letters in applied microbiology*, 58(6), 541-548.
21. Zhu , R. , Wang , Y. , Zhang , L. , ǝ Guo , Q. ( 2012 ) . Oxidative stress and liver disease . *Hepatology Research* , 42 ( 8 ) , 741-749